CNS EXAM
FOR NEUROLOGICAL DISEASES

Neurological Examination in Neonates, Infants and Children For Neurological Diseases

Sophelia Chan, MD

Clinical Associate Professor

Dept. of Paediatrics & Adolescent Medicine

Dec 2024

Tips for communicating with / examining Children

Names **Games** **interacting** **Parents 's help**

Warm hands

Praise

Gentle voice

Toys

PAEDIATRIC NEUROLOGICAL EXAM

General Observation/ Inspection	Conscious state / Alertness	Cranial nerves system
Motor system	Sensory system	Cerebellar system

NEUROLOGICAL EXAMINATION

- Neonates
- Infants
- Younger Children

Videos are from the Neurologic Exam and PediNeurologic Exam websites are used by permission of Paul D. Larsen, M.D., University of Nebraska Medical Center and Suzanne S. Stensaas, Ph.D., University of Utah School of Medicine. Additional materials for Neurologic Exam are drawn from resources provided by Alejandro Stern, Stern Foundation, Buenos Aires, Argentina; Kathleen Digre, M.D., University of Utah; and Daniel Jacobson, M.D., Marshfield Clinic, Wisconsin.

PAEDIATRIC NEUROLOGICAL EXAM

	Neonates	
General Observation/ Inspection	Observe Exam	Check OFC & plot on centile chart; Head shape. Dysmorphism & Deformity; Skin; External genitalia
Conscious state / Alertness	Observe Exam	Alertness; Responsiveness
Cranial nerves system	Observe Exam	Face (symmetry of facial expression) Eyes (spontaneous eye opening, ptosis)
Motor system	Observe Exam	Resting posture, active voluntary movement Muscle tone, Deep tendon reflex, Primitive reflexes
Sensory system	Observe Exam	Response to touch
Cerebellar system	Observe Exam	Nystagmus

Behaviour

Head control

Ventral & Vertical Suspension

Moro

Stepping

Galant

PRIMITIVE REFLEXES

Reflex	How to elicit…	Disappears at
Stepping	hold baby vertically & 'walk' with feet touching ground => feet move in stepping motion	2/12
Rooting	stroke cheek => mouth moving to that side	4/12
ATNR	rotate infants head to side x 15 secs => extension of limbs on side turned to with flexion of limbs on side turned away from	4/12
Palmar grasp	place index finger in palm of infant => flexion of fingers/makes fist	4/12
Moro	startle response	4-6/12
Galant	child held prone, stroke along side of spine on one side => flexion of trunk on that side	4-8/12
Plantar	extensor	until 1 yr old

PRIMITIVE REFLEXES

Primitive Reflexes

most are gone by 6 months of age

All are gone by 1 year of age

PAEDIATRIC NEUROLOGICAL EXAM

	Infant	
General Observation / Inspection	Expose & Observe	Check OFC & plot on centile chart, Head shape Dysmorphism & Deformity (face, hand, feet, spine) Skin, external genitalia
Conscious state / Alertness	Observe	Alertness Responsiveness
Cranial nerves system	Observe	Face (symmetrical face on crying) Eyes (spontaneous eye opening, visual follow) Bulbar (making sounds, feeding)
Motor system	Observe Exam	Resting posture, active movement, muscle bulk Muscle tone, Deep tendon reflex, Primitive reflexes Postural reaction (Parachute) Motor milestones (Gross motor, Fine motor)
Sensory system	Observe & Exam	Response to touch
Cerebellar system	Observe & Exam	Co-ordination , hand tremor, nystagmus

3 mths, ventral and vertical suspension

6 mths, active weight bearing; lateral propping postural reaction

12 mths, forward parachute and a few steps of toddler gait

PAEDIATRIC NEUROLOGICAL EXAM

	Younger children	
General Observation/ Inspection	Expose & Observe	Check OFC & plot on centile chart; Head shape. Dysmorphism & Deformity; Skin, external genitalia
Conscious state / Alertness	Observe	Alertness , Behaviour, Understanding
Cranial nerves system	Observe	Face (symmetrical face on crying) Eyes (spontaneous eye opening, visual follow) Bulbar (simple words, feeding)
Motor system	Observe Exam	Resting posture, active movement, muscle bulk Muscle tone, Deep tendon reflex, Motor milestones (Gross motor, Fine motor)
Sensory system	Observe & Exam	Response to touch
Cerebellar system	Observe & Exam	Co-ordination , hand tremor, nystagmus

PAEDIATRIC NEUROLOGICAL EXAM

- Level of alertness
- Attention / Social communication / Understanding of commands
- Like games

12 mths

18 mths

30 mths

PAEDIATRIC NEUROLOGICAL EXAM

	Older children	
General Observation/ Inspection	Expose & Observe	OFC & plot on centile chart, Head shape Dysmorphism & Deformity (face, hand, feet, spine) Skin, Heart, Abdomen
Conscious state / Alertness	Observe	Consciousness, Orientation (Time, Place), Knowledges Mini-mental state exam
Cranial nerves system	Observe	Similar to adult cranial nerve exam
Motor system	Observe Exam	Resting posture, active movement, muscle bulk Muscle tone, Deep tendon reflex, Muscle power
Sensory system	Observe & Exam	Response to light touch, pain, temperature Vibration, proprioception Cortical sensation: stereognosis, tactile discrimination, graphesthesia
Cordination and gait	Observe & Exam	Finger nose test, Heel to shin test, repetitive rapid hand movement Romberg test (stand with eyes closed) Gait (walking base, symmetry, stability, arm swing)

Cranial nerves	
I - olfactory	
II – optic – vision , fundal exam III - oculomotor IV – trochlear VI – abducens (false localising)	Eyes: Pupillary response; Visual acuity; Visual field; Eye movement
V – trigeminal : facial sensation (light touch), corneal reflex (with CN VII); jaw jerk reflex (absent), muscle of mastication VII – facial: facial symmetry (eg nasolabial), ask patient to smile, puff out cheeks, close eyes tight, wrinkle forehead, check taste (anterior part of tongue)	Face: Facial muscles control (Motor) Facial sensation (Sensory)
VIII – vestibulocochlear: hearing sound detection (finger rubs, whisper words) Whine and Weber test (bone vs conductive hearing loss) Vestibuloocular reflex, caloric test	Hearing
IX – glossopharyngeal X – vagal Palatal elevation (say ‘ AHHHHHHH’), gag reflex, check posterior tongue XII – hypoglossus: tongue muscle bulk, fasciculation; unilateral weakness	Bulbar (Speech & Swallowing)
XI – accessory : sternocleidomastoid/ trapezoid muscle Shrug the shoulders; turn head in both directions	
CN V, VII, IX, X, XII	Dysarthria or dysphagia

MBBS PAEDIATRIC CLINICAL SKILLS EXAMINATION VIDEOS

Platform: https://moodle.hku.hk/course/view.php?id=102111&section=13

UPPER MOTOR NEURON SIGNS
LOWER MOTOR NEURON SIGNS

	Upper Motor Neuron lesions	Lower Motor Neuron lesions
Muscles	Minimal to mild wasting	Wasting
Muscle tone	↑ Tone	↓Tone
Muscle power	Weakness	Weakness
Deep tendon reflexes	Hyperreflexia	Hyporeflexia / Areflexia
Clonus	Yes	No
Barbinski sign	Upgoing	Downgoing
Examples of lesions	Cerebral Palsy Stroke Brain tumour Congenital brain malformation (Lesions in the brain)	Muscular dystrophy Myopathy Spinal muscular atrophy Peripheral neuropathy (Lesions in the peripheral nervous system)

CONSCIOUS STATE / ALERTNESS

- A = Alert
- V = Responds to voice
- P = Responds to pain
- U = Unresponsive

Glassgow Coma Score			
≥ 4 years		≤ 4 years	
Response	Score	Response	Score
Eye opening		**Eye opening**	
Spontaneous	4	Spontaneous	4
To verbal stimuli	3	To verbal stimuli	3
To painful stimuli	2	To painful stimuli	2
No response to pain	1	No response to pain	1
Verbal response		**Verbal response**	
Oriented and converse	5	Alert, babbles, jargoning, usual words	5
Confused and converse	4	Less than usual babbling, jargoning, words	4
Inappropriate words	3	Cries only to pain	3
Incomprehensible sounds	2	Moans to pain	2
No response to pain	1	No response to pain	1
Motor response		**Motor response**	
Obey verbal commands	6	Spontaneous or obeys commands	6
Localises to stimuli	5	Localises to pain or withdraws to touch	5
Withdraws to stimuli	4	Withdraws from pain	4
Abnormal flexion to pain (decorticate)	3	Abnormal flexion to pain (decorticate)	3
Abnormal extension to pain (decerebrate)	2	Abnormal extension to pain (decerebrate)	2
No response to pain	1	No response to pain	1

Raised ICP

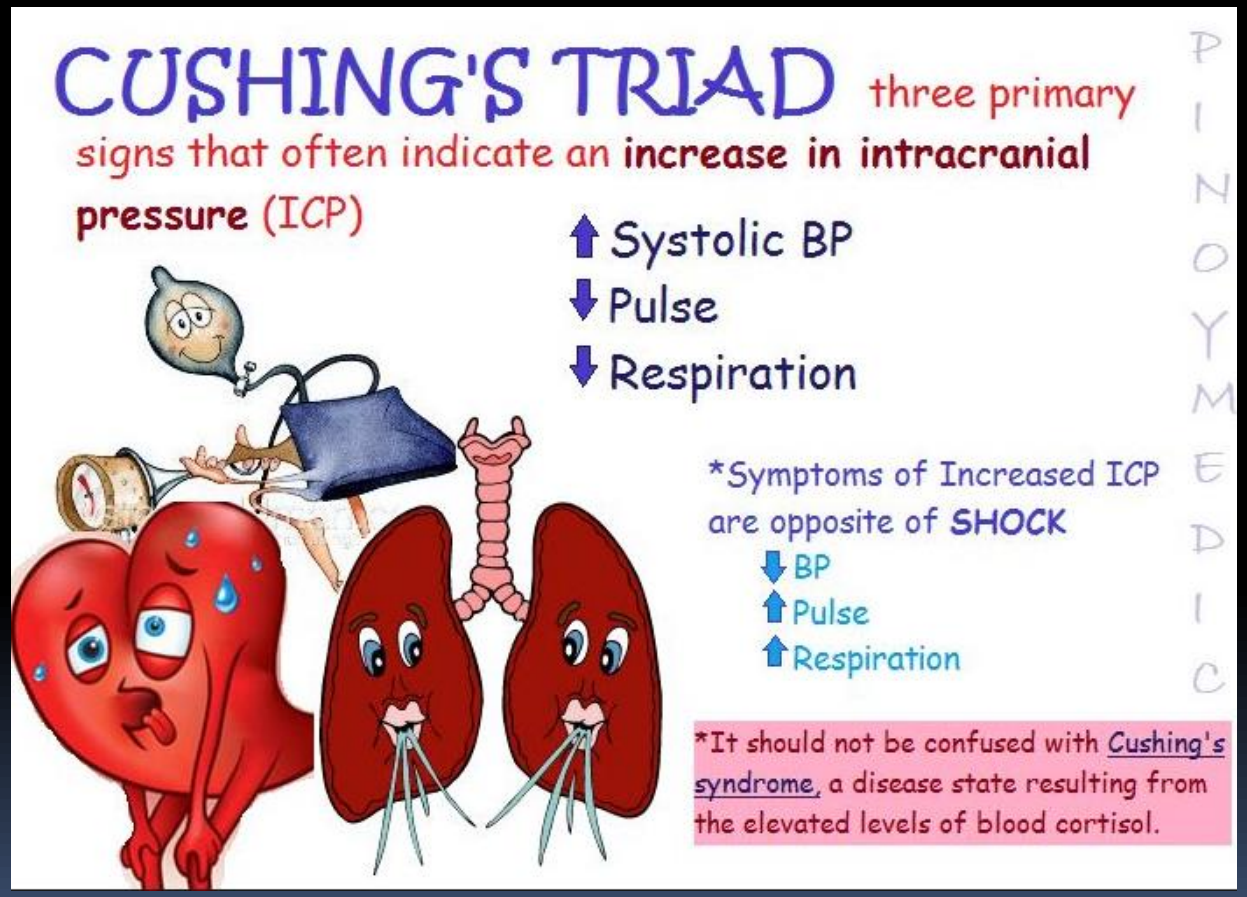

www.pinterest.com

Symptoms and Signs

Headache
Nausea and vomiting

Impaired conscious level
Papilledema
6th cranial nerve palsy : false localizing signs

Bulging anterior fontanelle (young baby)
Sunsetting eyes (young baby)

CNS EXAMINATION FOR NEUROLOGICAL DISEASES

Case sharing

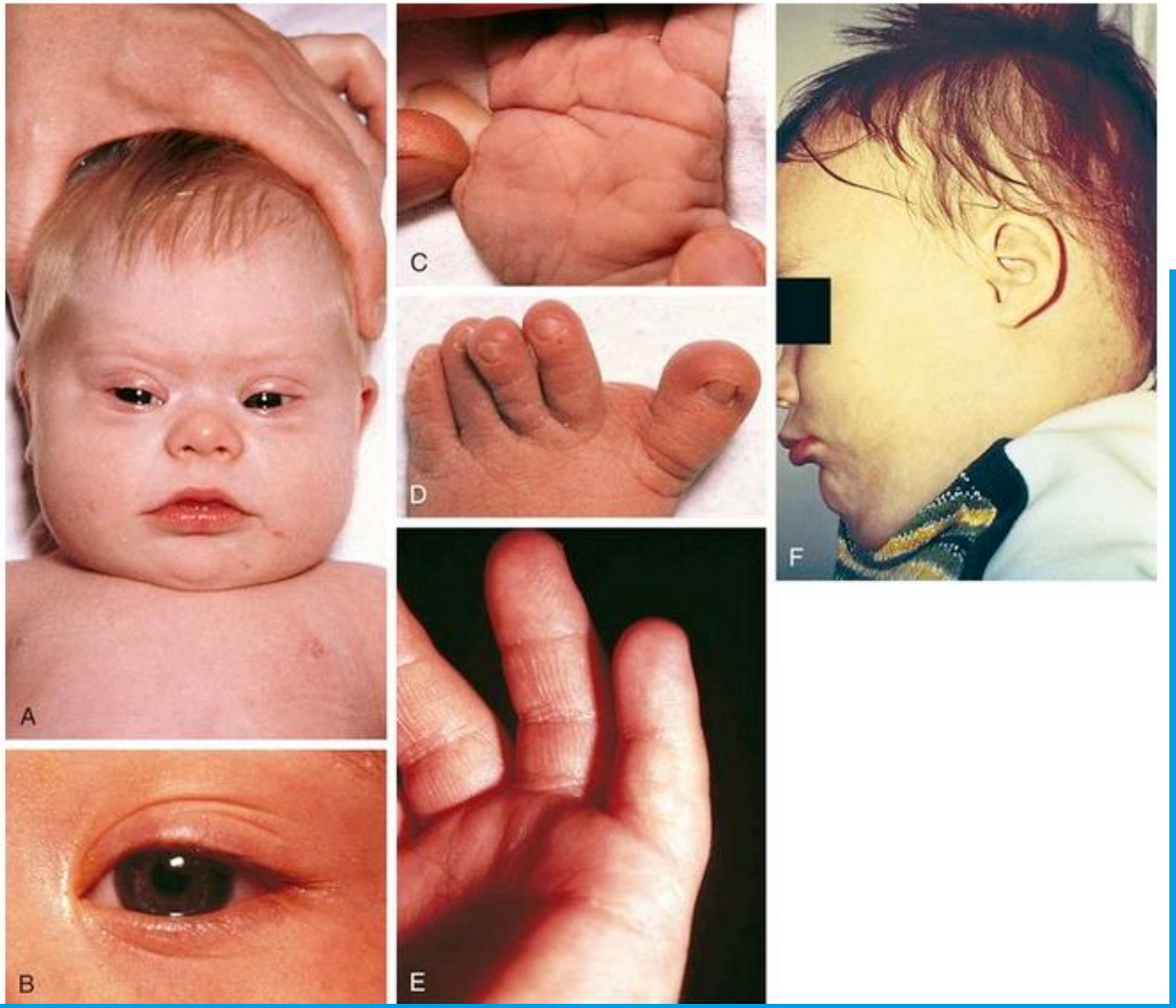

CASE 1. DYSMORPHISM

From: Genetic Disorders and Dysmorphic Conditions
Suneeta Madan-Khetarpal, Georgianne Arnold

CASE 2. ABNORMAL POSTURES AND MOVEMENT

CASE 3. ABNORMAL GAIT

CASE 4. WHAT IS THE POSITIVE SIGN ?

THANK YOU !
Q&A